
Short communication**Babsiosis in a new-born filly foal in
Bahrain – Case report****M. I. Abubakr, M. E. Fadlalla**Royal Court Laboratory, Manama
Kingdom of Bahrain

Babesiosis, due to *Babesia equi* was diagnosed in a new-born filly foal born to a carrier dam. The filly foal had haemolytic anaemia and died after two days despite receiving supportive and nonspecific treatment. The erythrocytes were heavily infected with *Babesia equi*. Clinical signs and post-mortem lesions are described.

Babesiosis is a tick – borne disease caused by the protozoan parasite of the genus *Babesia*. The disease is reported in cattle, sheep, equines, dogs, cats and pigs. It is characterized by fever, anaemia, haemoglobinaemia and haemoglobinuria (Blood and Radostits, 1989). *Babesia equi* and *Babesia caballi* infect equines mules donkeys, and zebras (Purneil, 1981 and Knowles and Uniss-Floyd, 1983).

This short communication describes the clinical signs and postmortem findings induced by *Babesia equi* infection in a new-born filly foal.

A full term filly foal was born on the 7th of February, 1996 at 21 30 hours and was of normal size but inactive. On the second day morning, its eyes appeared yellow but its body temperature was normal. A blood sample was drawn. The foal was given 3ml penicillin (150mg /ml.) intramuscularly and 1 litre of 5% glucose infusion. Fifteen hours later the foal passed bloody urine. It became dull, dehydrated, and anorexic. The foal was then given one pint of reconstituted horse powdered milk using a stomach tube and 500ml . of 5% glucose infusion. The foal became recumbent and died after 2 days of its birth.

At autopsy, the foal manifested pale mucous membranes. The liver, kidneys, and heart were icteric. The spleen was congested and the urinary bladder was distended with brownish – coloured urine.

Examination of Giemsa stained blood smears of the foal, revealed the presence of intraerythrocytic piroplasma. That were similar in morphology and size to those of *Babesia equi*. They were infecting most of the erythrocytes. They were pleomorphic, with round, oval and predominating ring forms. Pyriform bodies were 0.2 μ m. in length and were in groups of four with pointed ends meeting to form a maltese cross appearance which is characteristic of *Babesia equi* (fig 1). Packed cell volume was 28percent and the haemoglobin concentration was 10.8g /dl. Animal records revealed that the foal's dam was previously infected with *Babesia equi*. Giemsa – stained blood smears of the dam made few days after foaling were positive for *Babesia equi*.

The clinical signs reported in this investigation, the macro-anatomical features of the disease, and the morphology of the piroplasms showed a certain similarity to those induced by *Babesia* species infection in equines. Infection of the dam with morphologically similar parasite to that observed in the foal indicates that the dam was a carrier and could have transmitted the parasite to the foal. The route of infection of this foal was not known, but it is possibly prenatally acquired infection. The age of the foal (2 days) compared to the nature of the lesions and the residual *Babesia* infection in the dam supported the possibility of intrauterine transmission.

Acknowledgement:

The authors wish to thank Mr. Raja P. for his help in recording the clinical signs.

References:

1. Blood, D.C., Rodostits O. M. (1989): Vet. Med. Bailliere Tindall London, Philadelphia, USA pp 601
2. Purniel, R. E. (1981) : Babesiosis in Ristic, M. and Kreier, J. P. (Eds) Academic Press, New York. p 25 - 63
3. Knowles, R. C., and Uniss-Floyd (1983): Equine Pract.,5 (3),18

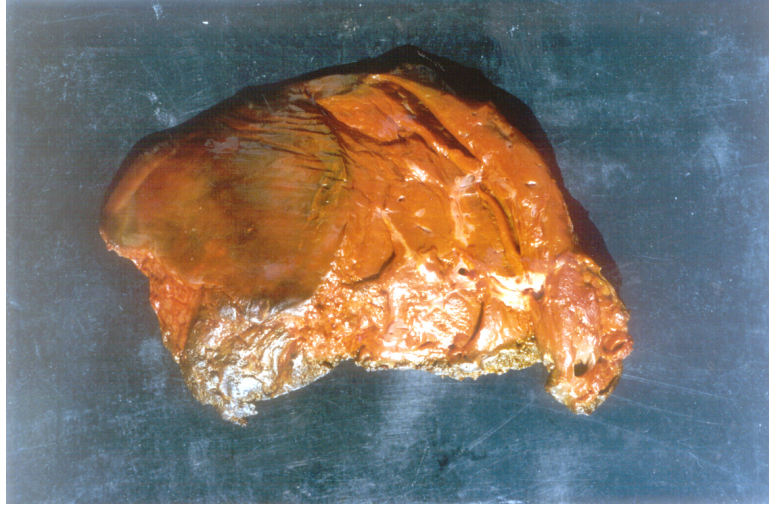


FIG. 1 Liver displaying yellowish discolouration (Icterus)

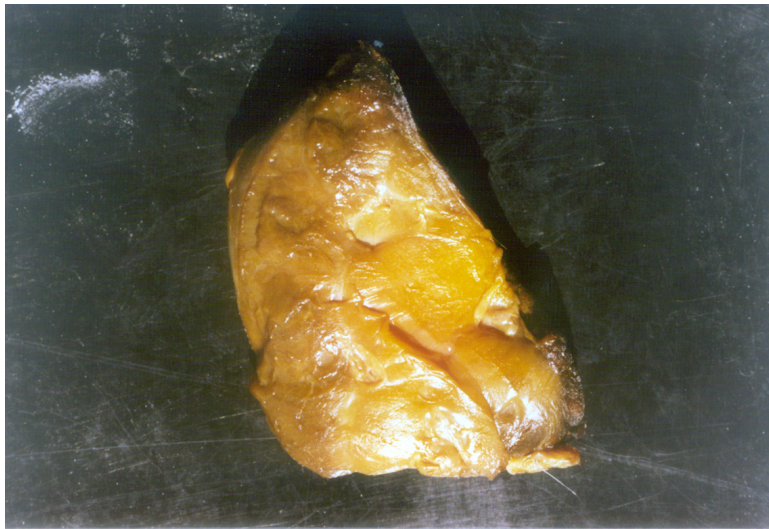

Fig.2 Kidney showing yellowish discolouration (Icterus)

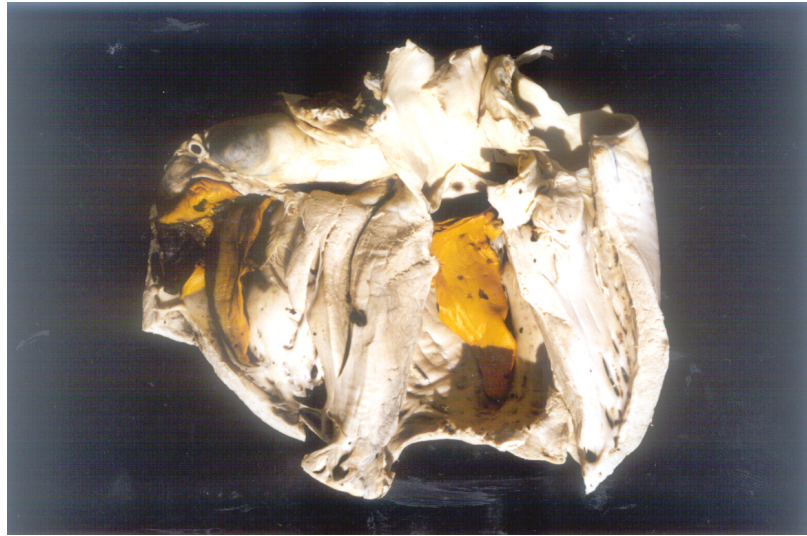


Fig.3 Heart showing yellowish discolouration (Icterus)

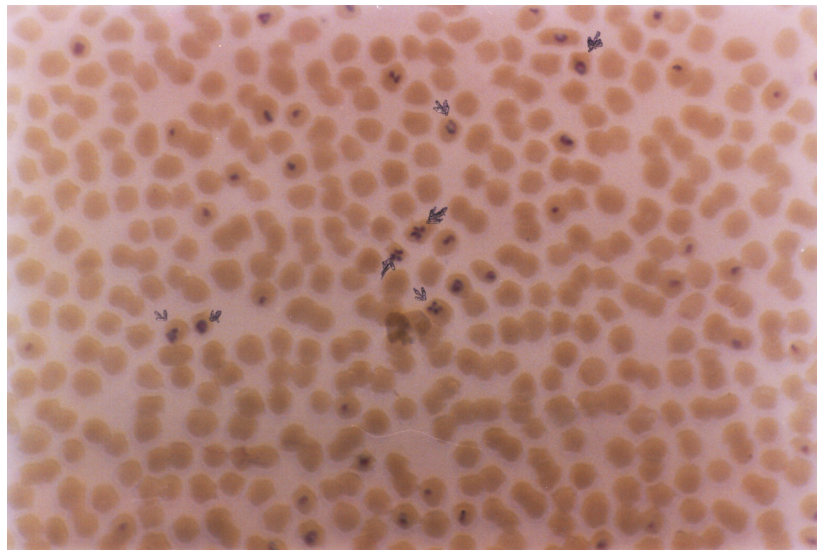


Fig.4 Blood smear showing various forms of *Babesia equi* in the red blood cells. Giemsa stain X 1000

بحث مختصر
تقرير عن إصابة فلو حديث الولادة بمرض
البابيزيا بهلكة البحرين

أبو بكر محمد إبراهيم أحمد و ميرغني الجيلاني فضل الله
الديوان الملكي
المنامة - مملكة البحرين

الملخص :

تسجل هذه الدراسة التي أجريت بدولة البحرين أول إصابة بمرض البابيزيا (بابيزيا إكوي) في فلو حديث الولادة لأم حامله لهذا المرض. ظهرت على الفلو عند الولادة حالة فقر الدم، ونفق بعد يومين من ولادته لعدم الإستجابة للعلاج. وقد أثبت الفحص المخبري لشرائح الدم الإصابة الكلية لكرويات الدم الحمراء بطفيل البابيزيا المسبب للمرض. كما بينت الدراسة الأعراض السريرية والتغيرات التشريحية المصاحبة للمرض.