
Laparoscopic Assisted Treatment of Cornual Ectopic Pregnancy – Case Report

Mona A. Almushait

Department of Obstetrics and Gynecology, Faculty of Medicine,
King Khalid University, Abha, Saudi Arabia.

Abstract:

This case report describes a medical treatment of cornual ectopic pregnancy which, in recent studies, was found to be safe, successful and associated with less subsequent complications than the traditional surgical treatment.

This cornual pregnancy was diagnosed by a positive high serum β -hCG level and laparoscopic examination. Seventy-five mg of Methotrexate was injected in the cornual pregnancy mass. The patient's condition was followed by sensitive quantitative serum assays and sonographic pictures. The patient was discharged from hospital after seven days in good condition. On follow-up, the cornual ectopic mass disappeared after two months. This was followed by a successful pregnancy and an elective caesarean section delivery of a normal mature baby.

Keywords: cornual pregnancy, laparoscopy, Methotrexate (MTX), transvaginal ultrasonography (TVS), β human chorionic gonadotropin (β -hCG)

Introduction:

An ectopic pregnancy in the interstitial portion of the fallopian tube is rare, occurring in 2–4% of all ectopic pregnancies¹³. It tends to rupture at a more advanced gestation compared to tubal ectopic pregnancy, and when ruptured, haemorrhage is usually profound⁴. The terms interstitial and cornual pregnancy are used interchangeably in published medical reports¹⁵.

The reported maternal mortality has remained high in the range of 2–2.5%, in contrast to 0.14% for tubal ectopic pregnancies¹³. The mortality rate of ruptured interstitial pregnancy is 2–5 times higher than that of tubal ectopic pregnancy⁴.

Over 10, 000 ectopic pregnancies are diagnosed in the UK annually, with the condition affecting 11 in 1000 pregnancies. Fortunately, although the incidence of ectopic pregnancy has increased over the last 25 years, there has been a decrease in the associated mortality⁸. This is most probably due to improved diagnostic techniques allowing ectopic pregnancies to be identified before the occurrence of high threatening events.

Transvaginal ultrasound is now able to delineate the eccentrically-located gestation sac early on; together with high index of suspicion and sensitive beta-human chorionic gonadotrophin (β -hCG) assay, it has made possible a preoperative diagnosis of interstitial pregnancy at an early gestational age before rupture occurs¹³.

Conservative management options include the local injection of potassium chloride, the use of minimally invasive surgical techniques and the administration of Methotrexate (1 mg of MTX per kg of body weight). This can be given either locally into the gestation or systematically as a single intramuscular dose or as multiple doses⁷. CBC and LFT were sampled every other day. Guided injection of MTX was performed either under TVS guidance or by hysteroscopy or laparoscopy¹¹.

Conventional management typically results in cornual resection or hysterectomy at the time of laparotomy. This not only has an immediate impact on patient morbidity, but also the consequences on subsequent term pregnancies are not clear and the risk of uterine rupture remains⁷.

This case report concludes that local methotrexate provides a safe effective method of treating cornual ectopic pregnancy. The use of laparotomy with hysterectomy or cornual resection should be reserved for those patients presenting late with a ruptured interstitial pregnancy, in whom conventional treatment of interstitial pregnancy has been cornual resection by laparotomy, local or systemic injection of methotrexate.

Case Report:

A 26-year old woman, G5P4A0, presented in the emergency department of King Faisal Military Hospital, Southern Region, Khamis Mushait, Saudi Arabia on the 5th of October 2008 complaining of vaginal bleeding, cramping and lower abdominal pain for one day. Her last menstrual period had been 2 months before (August 5, 2008). She had not been using any contraception. She had 3 normal deliveries, with babies' weight of 3.1 kg, 3 kg and 2.7 kg consecutively. The last delivery was an emergency caesarean section, 6 years ago with fetal weight of 3.2 kg.

The patient was normotensive, her weight was 75 kg and height was 142 cm. On pelvic examination, she had a slightly enlarged uterus with a closed cervix and a tender right adnexum. Her haemoglobin concentration was 12 g/dL, renal and liver function tests were normal.

A transvaginal ultrasonography (TVS) (Hitachi Model No. EUB 405 plus TVS probe 6.5 MHz) revealed an endometrial thickness of 12.9 mm

and a single intrauterine gestational sac (6 weeks) with a tiny fetal pole but no cardiac pulsation. She was diagnosed as missed abortion.

Because the patient was symptomatic, she was admitted to the Gynecology ward for management as a case of missed abortion at 8 weeks by her last menstrual period. The next day, she was given misoprostol 400 micrograms vaginally (a synthetic Prostaglandin analogue, brand name Cytotec ®). Six hours later, she started bleeding so, evacuation and curettage were done under general anesthesia. Minimal tissues were obtained and sent for histopathology. The patient was discharged with an appointment in the Gynecology clinic. After 3 days, the patient came to the emergency department complaining of passage of tissue and bleeding at home. On examination, she was afebrile, normotensive and her abdomen was soft with only mild suprapubic tenderness. Pelvic examination showed that the cervical os was closed, and there was no cervical excitation or tenderness. Although she went for curettage three days before, serum level of β subunit of human chorionic gonadotropin (β -hCG) (done by immunossary calibrated to WHO 3rd International Standard) was 5535 mIU/mL. Histopathology results showed no chorionic villi. A 4D scan (GE Voluson 730, 6.5 MHz transvaginal probe) suspected a right cornual ectopic pregnancy with empty uterine cavity, and a gestational sac about 20 x 25 mm eccentric mixed echogenic shadow on the right cornu and mild pelvic collection. Arrangements were made for emergency laparoscopy and possible laparotomy and consent taking. Four units of blood were prepared.

Following the laparoscopic setup and under general anesthesia, the patient was placed in steep Trendelenberg position. The patient was monitored continually for blood pressure, electrocardiogram, transcutaneous oxygen saturation, and end tidal carbon dioxide pressure. A vertical incision was made subumbilically and a Verrus needle was inserted with the tip aiming towards the Pouch of Douglas for insufflation. A 10 mm laparoscope was inserted subumbilically and two 5 mm trocars were inserted in the suprapubic region and lateral to the inferior epigastric vessels.

We used 5 mm instruments: grasping forceps without teeth, bipolar diathermy forceps and laparoscopic aspiration needle. Haemostasis was secured and laparoscopic findings revealed right cornual pregnancy about 2.5 x 2 cm. It looked highly vascular. The rest of the uterus was normal. Both ovaries and tubes were healthy. Seventy-five mg of Methotrexate (MTX)–(antimetabolites) was injected locally in the cornual mass, and bleeding points were cauterized by bipolar diathermy forceps.

Postoperatively, the patient was kept in the Gynecology ward under observation and her postoperative course was uncomplicated. On day 4 of local MTX injection by laparoscopy, β -hCG was 3396 mIU/mL and on day 7 it was 840 mIU/mL. On TVS, mass size decreased to 1.4 x 1.3 cm, both ovaries were normal and there was no fluid in the Pouch of Douglas (*Figure I*). The patient was given advice of no intercourse for one month then discharged home with a weekly follow-up appointment in the Gynecology clinic for serial serum β -hCG estimation and ultrasonographic examination.

After one month of the local Methotrexate injection, the β -hCG was less than 2 and on TVS, no mass was detected. The uterus was of normal size and both ovaries were normal (*Figure II*). The patient was advised to take oral contraceptive pills (Marvelon–Ethinylestradiol, Desogestrel, Organon) for six months, but due to poor compliance, she did not follow the instructions. After 6 months from discharge, she came to the clinic with a history of missed period for seven weeks and was diagnosed as intrauterine pregnancy. She was followed up in the antenatal clinic as a high-risk pregnancy because of her previous history of caesarean section and cornual ectopic pregnancy. During the antenatal follow-up, ultrasound showed small for gestation age at 3rd trimester but no other abnormalities. Elective caesarean section was done at 38 weeks and she delivered a baby girl of 2.365 kg weight with Apgar score of 8 at 1 minute, 9 at 5 minutes and 9 at 10 minutes. During the operation, the uterus was found weak at the right cornual end. The patient was discharged on the third day of operation with a healthy baby and no complaints, and was given an appointment in postnatal clinic after 4 weeks.

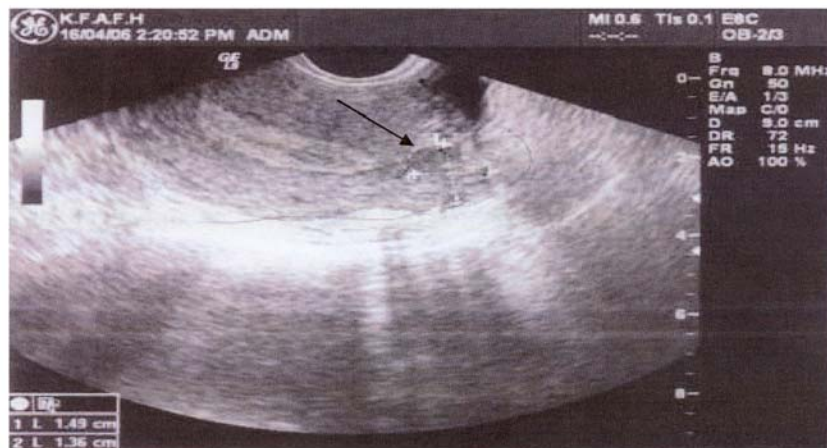


Figure (I) : TVS on day 4 of Methotrexate injection

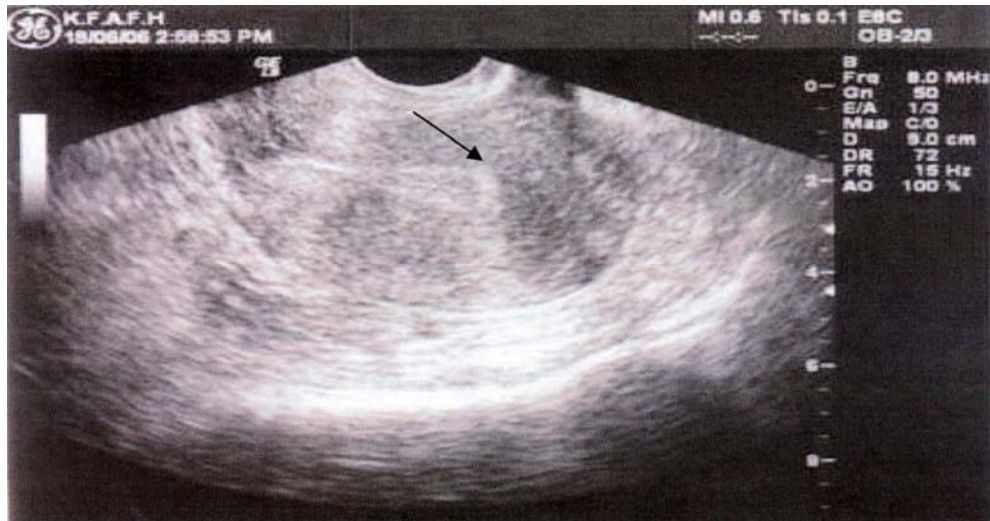

Figure (II): TVS after 1 month of Methotrexate injection

Discussion:

Cornual pregnancy poses a significant diagnostic and therapeutic dilemma. The interstitial portion of the fallopian tube is the proximal portion that is within the muscular wall of the uterus. It is 0.7 mm wide and 1 to 2 cm long. Cornual (interstitial) pregnancy represents about 1% of the ectopic pregnancies¹¹. It carries a higher maternal mortality risk compared with the more common tubal pregnancies. The associated maternal mortality rate is 2%–3%, with four deaths reported in the Confidential Enquiry into Maternal and Child Health report for 2000–2002⁵.

Risk factors for cornual pregnancy include past pelvic inflammatory disease, previous pelvic surgery, uterine anomalies, the use of assisted reproductive techniques, and ipsilateral salpingectomy¹¹.

The traditional management of cornual pregnancy was laparotomy with either cornual resection or hysterectomy. More recently, conservative therapeutic measures for early cornual ectopic pregnancy have been advocated in published reports^{7,13}. Moon et al.⁹ described three laparoscopic methods which have been used successfully: The vasopressin electric cauterization, the endoloop and the encircling suture methods. The authors advised subsequent delivery by elective caesarean section before the onset of labor because of the increased risk of uterine rupture. Bhaskar pal et al.³ reported the successful hysteroscopic management of cornual ectopic pregnancy. Laparoscopic cornuostomy in the treatment of interstitial pregnancy has also been reported¹⁶.

Both surgical and medical treatments for cornual gestation exist, each is not without its shortcomings. Medical treatment is associated with failure rates that may result in uterine rupture and catastrophic haemorrhage. Surgical treatment that involves hysterectomy causes a loss of future childbearing capability. Surgical treatment that involves resection of the involved cornual region is associated with decreased fertility rates and increased rates of uterine rupture in future pregnancies^{10, 11}.

Combined laparoscopy and methotrexate injection used to treat cornual pregnancy was reported by Ross et al¹⁰. We treated this patient conservatively by laparoscopy to avoid any possible future compromise to her reproductive function.

The reported case was in early pregnancy. The diagnosis was suggested by TVS salient features. The 75 mg of methotrexate single dose, calculated as 1 mg/kg of body weight, was used successfully by local injection into the sac by the laparoscope.

Methotrexate (generic name: methotrexate); (brand names: Rheumatrex Dose Pack, Trexall) is typically given by injection for ectopic pregnancy. Two injection sites are sometimes used to administer one dose. This increases absorption of all the medicine. Methotrexate can be given by mouth. But ectopic pregnancy treatment success rates are lower with oral use than with injections. It stops the growth of rapidly dividing cells such as embryonic, fetal, and early placenta cells. Methotrexate can be used to end an early ectopic pregnancy, to prevent the growth of any embryonic or fetal cells that are left behind after surgery and it is also used to treat certain types of cancer, rheumatoid arthritis, and as part of an induced abortion. Methotrexate treatment is most likely to be successful when β -hCG levels are low (less than 5,000), during the first 6 weeks of pregnancy and when the embryo has no heart activity. Common side effects of methotrexate treatment for ectopic pregnancy include: Abdominal pain, vaginal bleeding or spotting, nausea, vomiting, indigestion, fatigue and dizziness².

With advances in the diagnostic procedures and surgical techniques,¹⁴ a variety of minimally invasive interventions⁶ have been implemented to treat interstitial pregnancy. The successful outcome in treatment of interstitial pregnancy with the use of different methods depends on clinical symptoms, gestational age, pregnancy viability, uteroplacental neovascularization and the patient's own views and preferences. Of these, assessment of uteroplacental neovascularization around the cornual portion of the uterus should be the most important factor in the determination of which form of treatment is justified¹².

Conclusion:

In conclusion, a cornual gestation is one of the most hazardous types of ectopic gestation with high mortality. Cornual ectopic pregnancy is difficult to diagnose and management options are always challenging. The availability of high resolution ultrasonography, experienced gynecological sonographer and sensitive quantitative serum β -hCG assays are essential to the diagnosis of cornual ectopic pregnancy. Conservative management strategies require good patient compliance and regular follow-up. This type of management has the advantage of avoiding major surgery. It may maintain fertility by a reduction in adhesion formation. Furthermore, it helps to avoid potential surgical trauma to the uterus.

Currently, there is insufficient evidence to recommend any single treatment modality for cornual gestation. The decision should be based on such factors as clinical presentation, surgeon's expertise, side effects, overall cost and patient's preference.

References:

1. Al Inizi, S. Cheema, M. and Bamigboye, V. 2007. Conservative Laparoscopic and Medical Treatment for Cornual Pregnancy. *The Internet Journal of Gynecology and Obstetrics*, 7: No.1.
2. American Society of Reproductive Medicine 2006. Technical bulletin: Medical Treatment of Ectopic Pregnancy. *Fertility and Sterility*, 86(4): S96–S102.
3. Bhaskar, P. Olayinka, A. and Harrington, K. 2003. Hysteroscopic Management of Cornual Ectopic Pregnancy. *BJOG*, 110: 879-880.
4. Chan, L.Y. Fok, W.Y. and Yuen, P.M. 2003. Pitfalls in Diagnosis of Interstitial Pregnancy. *Acta Obstet Gynecol Scand*, 82: 867–870.
5. Confidential Enquiry Into Maternal and Child Health report: “Why Mothers Die,” The Sixth Report of the Confidential Enquiries into Maternal Deaths in the United Kingdom. RCOG Press, London 2004. 2000–2002.
6. Deruelle, P. Lucot, J.P. Lions, C. and Robert, Y. 2005. Management of Interstitial Pregnancy Using Selective Uterine Artery Embolization. *Obstet Gynecol*, 106: 1165–1167.
7. Jermy, K. Thomas, J. Doo, A. and Bourne, T. 2004. The Conservative Management of Interstitial Pregnancy. *BJOG*, 111: 1283-1288.
8. Kirk, E. Bourne, T. 2006. The Nonsurgical Management of Ectopic Pregnancy. *Current Opinion in Obstetrics and Gynecology*, 18: 587–593.
9. Moon, HS. Choi, YJ. Park, YH. and Kim, SG. 2000. New Simple Endoscopic Operations for Interstitial Pregnancies. *Am J Obstet Gynaecol*, 182: 114-121.
10. Ross, R. Lindheim, SR. Olive, DL. and Pritts, EA. 2006. Cornual Gestation: A Systemic Literature Review and Two Case Reports of a Novel Treatment. *J Minimally Invasive Gynecol*, 13 (1): 74–78.
11. Soriano, D. Vicus, D. and Maschiach, R. 2008. Laparoscopic Treatment of Cornual Pregnancy: A Series of 20 Consecutive Cases. *Fertil Steril* 90: 839–843.
12. Takeda, A. Koyoma, K. and Imoto, S. 2008. Successful Management of Interstitial Pregnancy with Fetal Cardiac Activity by Laparoscopic-Assisted Cornual Resection with Preoperative Transcatheter Uterine Artery Embolization. *Arch Gynecol Obstet*, doi: 10.1007/s00404-008-0896-9.
13. Tang, A. Baartz, D. and Khoo, S. 2006. A Medical Management of Interstitial Ectopic Pregnancy, a 5-year Clinical Study. *Australian and New Zealand Journal of Obstetrics and Gynaecology*, 46: 107-111.
14. Valsky, D.V. Hamani, Y. Verstandig, A. and Yagel, S. 2007. The Use of 3D Rendering, VCI-C, 3D Power Doppler and B-flow in the Evaluation of

Interstitial Pregnancy with Arteriovenous Malformation Treated by Selective Uterine Artery Embolization. *Ultrasound Obstet Gynecol*, 29: 352–355.

15. Verity, L. Ludlow, J and Dickinson, J.E. 2003. Interstitial Ectopic Pregnancy: A Contemporary Case Series. *Australian and New Zealand Journal of Obstetrics and Gynaecology*, 43: 232–235.
16. Yoo, E. Chun, S. and Kim, J. 2003. Endoscopic Treatment of Interstitial Pregnancy. *ACT Obstet Gynecol Scand*, 82: 189-191.

علاج حمل قرني بواسطة المنظار : دراسة حالة

منى عبدالله آل مشيط

قسم النساء والتوليد ، كلية الطب ، جامعة الملك خالد
أبها ، المملكة العربية السعودية

الملخص :

تصف دراسة هذه الحالة العلاج الطبي لحمل في الجزء القرني من الرحم، والذي أثبتت الدراسات الحديثة انه علاج آمن وناجح ولا يؤدي لمضاعفات مثل العلاج الجراحي التقليدي.

وقد تم تشخيص هذا الحمل القرني بوجود نسبة عالية من هرمون المشيماء في مصل الدم والفحص بالمنظار.

تم حقن خمسة وسبعين ملجم من عقار الميثوتريكسات في كتلة الحمل القرني وتمت متابعة حالة المريضة بفحص كمي لهرمون المشيماء وبصورة الموجات فوق الصوتية وبالمتابعة اختفت كتلة الحمل القرني بعد شهرين، وعقب ذلك تبع بحمل ناجح وولدت العملية قيصرية اختيارية طفلاً كاملاً النمو

الكلمات المرجعية : حمل قرني، منظار البطن ، عقار ميثوتريكسات ، جهاز الموجات فوق الصوتية ، هرمون المشيماء .