

## Opportunistic Bacteria Isolated from Trypauchen Vagina Fish that Infected with Protozoan from Iraq Marine Water

Nadia Ali Al-Shammari

Biological Development Department, Marine Sciences Centre, University of Basra, Basra, Iraq

## البكتيريا الانتهازية المعزولة من أسماك Trypauchen vagina المصابة بالطفيليات الأولية في المياه البحرية العراقية

نادية علي الشمري

قسم التطور الإحيائي، مركز علوم البحار، جامعة البصرة، البصرة، العراق



LINK الرابط	RECEIVED الاستقبال	ACCEPTED القبول	PUBLISHED ONLINE النشر الإلكتروني	ASSIGNED TO AN ISSUE الإحالة لعدد
<a href="https://doi.org/10.37575/b/vet/0036">https://doi.org/10.37575/b/vet/0036</a>	04/10/2020	15/12/2020	15/12/2020	01/06/2021
NO. OF WORDS عدد الكلمات	NO. OF PAGES عدد الصفحات	YEAR سنة العدد	VOLUME رقم المجلد	ISSUE رقم العدد
3110	4	2021	22	1

### ABSTRACT

Opportunistic bacteria are microorganisms that have been isolated from a host suffering from stress as a result of parasitic infestation. In this study, two bacterial species, namely *Aeromonas hydrophila* and *Rhizobium radiobacter*, were isolated from *Trypauchen vagina* fish that were infected with Microsporidian parasite cysts from Iraqi marine waters. The infection were mass implanted in the internal and external skeletal muscles and under the gill cover. Many symptoms of bacterial infection were observed in the fish, including flatulence with haemorrhagic fluids, skin discoloration blackening, separation of crusts, and deformities in the area. The two bacterial species were characterised morphologically and identified using Vitek II system (Biomerieux - USA). To control infection, antibiotic susceptibility was performed using six antibiotics: nalidixic acid, nitrofurantoin, gentamicin, streptomycin, tetracycline and amoxicillin, both bacteria showed high antibiotic resistance. Identification of opportunistic bacteria has a pivotal role in preventing stress factors in fish, treating infections and alleviating their impact on other aquatic organisms.

### المخلص

البكتيريا الانتهازية هي كائنات دقيقة تم عزلها عن مضيف يعاني من الإجهاد نتيجة الإصابة الطفيلية. وفي هذه الدراسة الحالية، تم عزل نوعين من البكتيريا *Aeromonas hydrophila* و *Rhizobium radiobacter* عن أسماك القوبيون *Trypauchen vagina* المصابة بخراجات طفيلية Microsporidian، في المياه البحرية العراقية. لوحظ العديد من أعراض الإصابة البكتيرية على الأسماك، منها انتفاخ البطن المصاحب للسوائل النزفية، وتغير لون الجلد، من حيث أسوداد المنطقة، وانفصال القشور عن مكانها، وكذا تشوهات في المنطقة أيضاً. لهذا حصل عزل الأنواع البكتيرية عن الأسماك التي شُخصت البكتيريا فيها، تبعاً لكل من الصفات المظهرية، وباستخدام جهاز تشخيص البكتيريا (Vitek II). تبيّنت الإصابة الطفيلية في عضلات الهيكل العظمي الداخلية والخارجية، وتحت غطاء الخياشيم. وللسيطرة على العدوى، ومعرفة كيفية استجابة البكتيريا للمضادات الحيوية، وُظفّت ستة أنواع من المضادات الحيوية هي حمض الناليديكسيك، نتروفورانتوين، الجنتاميسين، الستربتومايسين، التتراسيكلين والأموكسيسيلين، التي أظهرت سلالات بكتيرية مقاومة أقوى للمضادات الحيوية. إن تحديد البكتيريا الانتهازية له أهمية في الوقاية من العوامل التي تُسبب إجهاد الأسماك، والعمل على معالجتها، وتقليل تأثيرها على الأحياء المائية الأخرى.

### KEYWORDS

#### الكلمات المفتاحية

*Aeromonas hydrophila*, microsporidian parasite, *rhizobium radiobacter*

ايروموناس هيدروفيليا، رايوزيوم بكتيريا، الطفيليات الأولية

### CITATION

#### الإحالة

Al-Shammari, N.A. (2021). Albiktiria alaintihaziat almaezulat min 'asmak Trypauchen vagina almusabat bialtafilial al'awaliat fi almiyah albahriat aleiraqia 'Opportunistic bacteria isolated from Trypauchen vagina fish that infected with protozoan from Iraq marine water'. *The Scientific Journal of King Faisal University: Basic and Applied Sciences*, 22(1), 83–6. DOI: 10.37575/b/vet/0036

الشمري، نادية علي. (2021). البكتيريا الانتهازية المعزولة من أسماك Trypauchen vagina المصابة بالطفيليات الأولية في المياه البحرية العراقية. *المجلة العلمية لجامعة الملك فيصل: العلوم الأساسية والتطبيقية*، 22(1)، 83-86.

## 1. Introduction

Opportunistic bacteria are characterised by virulent factors, that attack the host's defences and, thus, reduces its immunity (Derome *et al.*, 2016). Disturbances in the host occur for many reasons (immunodeficiency, pathological infection and wound), and atypical environmental factors constitute an ideal environment for opportunistic bacteria to grow (Austin and Austin, 2007). Protozoa is one of the most important parasites that cause infections in fish in the form of tumours or cystic masses, and they cause deformities in the external appearance of the fish (Lom and Dykova, 2005). *Trypauchen vagina* has eyes that are completely covered with skin and the front part of its head is protected by dense flesh. In a natural environment, it lives in marine and brackish water (Bhagirathan *et al.*, 2012). The bacteria in fish only become pathogens when fish are physiologically unbalanced, nutritionally deficient, or there are other stresses (Donia *et al.*, 2018). *Aeromonas* spp. and *Pseudomonas* spp. organisms that cause the death and disease of many fish are widely distributed in water (Al-Shemmari, 2017). *Rhizobium radiobacter* is originally characterised as an endo fungal bacterium, an uncommon

opportunistic pathogen present in soil as an aerobic gram-negative belonging to the *Agrobacterium* genus (Guo *et al.*, 2017; Marta *et al.*, 2011). Furthermore, *A. hydrophila* has been recorded in three marine fish species from the North West Arabian Gulf, Iraq (Al-Maleky and Hanafi, 2013). *A. hydrophila* can be isolated from estuarine waters, marine, brackish and freshwaters and freshwater environments that have an especially high organic load. Recent evidence from Japan and the USA suggests that it may also be a part of the resident gut flora of fish (Sreedharan and Philip, 2012; Dias *et al.*, 2016). Most of the studies in Iraq focus on infecting fish with bacterial strains in fresh water and few studies focus on fish in Arabian Gulf waters. This study focuses on opportunistic bacteria and their characteristic due to their association with parasitic infections.

## 2. Materials and methods

### 2.1. Fish Samples Collection:

A total of 28 live *Trypauchen vagina* fish were collected from Iraq marine water, during July 2018. The fish samples were stored

individually in sterile bags placed in sterile bags and placed in a cold box at the Department of Biological Development. Fish were identified according to (Carpenter *et al.*, 1997).

**2.2. Bacteria Isolation:**

Bacterial swabs were taken from skin lesions of infected fish, cultured on general media with nutrient agar (Hi-Media , India) and incubated at 37 °C for 48 hours. Pure bacterial cultures on the 5% sheep blood agar (Hi-Media, India) were enriched, using the spread plate method and the plates were incubated at 37 °C for 24 hours. The bacterial colonies underwent phenotypic identification morphologically by colony size along with hemolytic and Gram staining (Fig.3) reactions (Cheesbrough, 2000). Two strains of bacterial colonies appeared; *Rhizobium radiobacter* appeared as anon-haemolytic colony(Fig.2. A) and *A. hydrophila* appeared as a beta-hemolytic colony (Fig.2.B). They were identified by the VITEK II system (Biomerieux- USA).

**2.3. Antibiotic Susceptibility**

Antibiotic susceptibility testing was carried out using the disc diffusion method, according to CLSI (2006). The six different discs of antibiotic were: nalidixic acid (NA) 30 mg, nitrofurantoin (F) 300 mg, gentamicin (CN) 10 mg, streptomycin (S) 10 mg, tetracycline 30 mg, amoxicillin (AX) 25 mg (Fig. 3). Six antibiotics were tested in sterile distilled water and spread over the surface of the Mueller-Hinton agar (Hi-Media, India) plate. After drying, the antibiotic discs were placed over the plates and incubated at 37°C for 24 h. The degree of sensitivity of the isolates to six antibiotics was determined by measuring the zone of clearance around the antibiotic discs.

**3. Results and discussion**

**3.1. Bacterial Diagnosis:**

The isolated bacteria obtained from the skin and gill covers were identified as *Rhizobium radiobacter* and *Aeromoans hydrophila*. They were recorded with a parasitic infection, with symptoms occurring as a result of clinical abnormalities. The fish were infected with the *Microsporidian* cysts, and the infection appeared as a mass embedded in the internal and external skeletal muscles and gill. The infection took the form of whitish cylindrical tumour-like masses up to 2–4 cm in diameter (Fig. 1). The pathological observations were of a parasitic mass filled with mature spores encapsulated by a fibrous layer. To find out the extent to which bacteria suppressed antibiotics, a bacterial allergy sensitivity test was performed as shown in Table 1.

Fig 1. *Trypauchen vagina* infected with *Microsporidian* sp. (a, b) (Lom and Dykova, 1992)

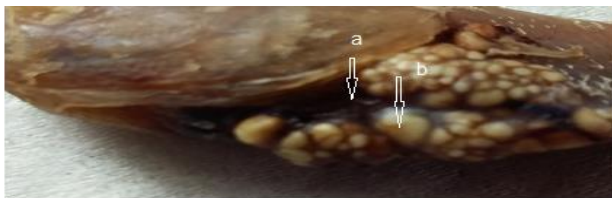

Fig 2. (A) *R. radiobacter* colony appears as anon-haemolytic colony and (B) *A. hydrophila* appears as beta-hemolytic colonies on enriched blood agar

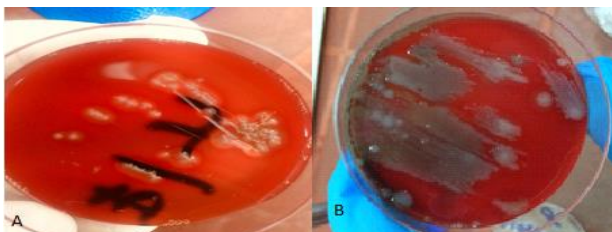


Fig 3. Cell morphology, Gram staining of isolated bacterial strains *A. hydrophila* (A), *R. radiobacter* (B). Gram stained negative rods from asheep blood culture bottle were observed (magnification ×1000)

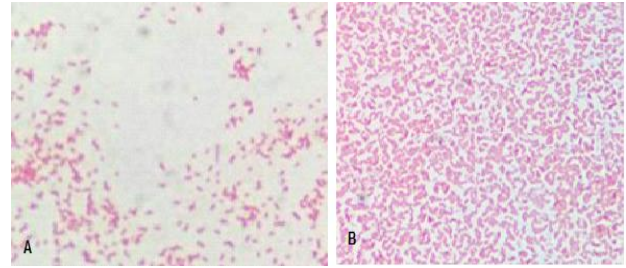


Table 1. Antibiotic resistance of *R. radiobacter* and *A. hydrophila*.

Antibiotics	Concentration (mcg/g)	Symbol	<i>R. radiobacter</i> diameter of zone inhibition in(mm)	Type of Resistance	<i>A. hydrophila</i> Diameter of zone inhibition in(mm)	Type of Resistance
Nalidixic acid	30	NA	18	S	25	S
Nitrofurantoin	300	F	8	R	-----	R
Gentamicin	10	CN	30	S	18	R
Streptomycin	10	S	7	R	11	R
Tetracycline	30	TE	30	S	4	R
Amoxicin	25	AX	7	R	29	S

Antibiotics: nalidixic acid (NA) 30 mcg, nitrofurantoin (F) 300 mcg, gentamicin (CN) 10 mcg, streptomycin (S) 10, tetracycline (TE) 30 mcg, Amoxicin (AX) 25 mcg. R: resistance (mm), S: sensitive (mm). CLSI (2006).

**3.2. Clinical Pathologic Examination:**

Pathologic examination showed extensive damage to the host tissue, including epithelial necrosis, haemorrhage and the presence of encrusted spores in the skeletal muscles of the fish. These caused lesions, including mild hyperplasia of fibrous connective tissue around the parasite, and observations showed that the parasitic foci were encapsulated by fibrous layers and were filled with spores. With the parasitic infection, the initial observations showed symptoms of bacterial infection, such as changing the colour of the skin, the presence of haemorrhagic fluids, necrosis in the affected area, and the shedding of crusts as the host was a congregation area for several microscopic organisms in a close relationship without killing the host. *A. hydrophila* and *R. radiobacter* were opportunistically infected with *Microsporidian* parasite cysts embedded in the peritoneal cavity and gills which appeared as whitish cylindrical tumour-like masses up to 2–4 cm, in diameter. The pathological observations found a parasitic mass filled with mature spores encapsulated by a fibrous layer that was spread in adult *Trypauchen vagina* fish, but the intensity of infection was very low (1.22%).

Numerous studies have discussed the role of pathogenic bacteria and the ability of pathogens to exacerbate symptoms (Darby *et al.*, 2002). The coexistence of the bacteria and parasite in the same host without causing damage to the host and without the affected area dying, is called endocytosis (Fehrenbacher *et al.*, 2011). In fish farms in the Basra Governorate, Iraq, Al-Shemmari (2017) infected the gills of *cyprinus carpio* fish with the *Ascocotyle* parasite, which was accompanied by a bacterial infection with bacteria *Escherichia coli*. The eyes of *Planiliza subviridis* fish were also infected with the *Diplostomat spathaceum* parasite and were diagnosed with a parasitic infection.

*A. hydrophila* is an opportunistic pathogenic bacteria, that causes many diseases, such as haemorrhagic septicemia, ulcerous dermatitis and epizootic ulcerative syndrome in numerous fresh water and marine species (Hung *et al.*, 2009) Symptoms included darkening of the skin, necrosis and erosion; furthermore, when the injury develops, bleeding and occur. Bacteria are isolated from the aquatic environment and from the surface of the body and intestine (Noga, 2010 ; Al-Shemmari, 2017); symptoms were similar to this study where the opportunistic bacteria were isolated.

Donia *et al.* (2018) infected tilapia fish with *Rhizobium radiobacter*,

which is symbiotic and widespread the El Salam Canal, Northern Sinai, Egypt. A host can have many symbionts with different individuals or the same individual, and symbiotic societies may influence the host phenotype (Oliver *et al.*, 2003). Antibiotics have treated many common bacterial infections. However, the massive use of antibiotics since their introduction as medications has increased the incidence and spread of antibiotic-resistant bacteria (Romero and Navarrete, 2012). *A. hydrophila* spreads everywhere in the aquatic environment and causes infection in many aquatic organisms. Its resistance to antibiotics may develop due to its own resistance to  $\beta$ -lactam antibiotics, such as ampicillin, which affects the permeability of the outer membrane and its ability to obtain antibiotic-resistant genetic elements (Manuel *et al.*, 2019; Knochel, 1989). Various antibiotics have been studied, and results indicate that *A. hydrophila* isolates have been resistant to tetracycline, amoxicillin, gentamicin, streptomycin sensitive to nitrofurantoin and is intermediately resistant to nalidixic acid (Stratav and Olumide, 2015). Some bacteria appears to be resistant to antibiotics, even with maximum doses, according to Janda and Abbot (2010). The resistance of microorganisms to antibiotics develops as resistance to them occurs (Putra *et al.*, 2019). The results showed that *A. hydrophila* is resistant to gentamicin, streptomycin, tetracycline and amoxicillin, which is similar to the results observed by Hazen *et al.* (1978). Olumide and Ahmad (2015) studied different geographic areas and suggested that selective pressures can affect local antibiotic resistance; this was also observed in *A. hydrophila* isolates that were resistant to nitrofurantoin. This is why bacteria poses a threat to public health, animals and the aquatic environment (Hazen *et al.*, 1978). *R. radiobacter* was also resistant to nalidixic acid, tetracycline, and amoxicillin. It was intermediately resistant to gentamicin, nitrofurantoin and streptomycin; its resistance to tetracycline was higher, which agrees with Jaafar (2019). Fish health and treatment services must be coordinated with fishery engineers, aquaculture specialists or aquacologists because fish health is a necessity in our country and should be taken into consideration.

#### 4. Conclusions

Two species of bacteria, *Aeromonas hydrophila* and *Rhizobium radiobacter*, were isolated from *Trypauchen vagina* fish that were infected with *Microsporidian* parasite cysts. The presence of opportunistic bacterial pathogens is unhealthy for fish and exposes them to the risk of infection, especially when immunocompromised.

#### 5. Acknowledgments

Thanks to the Biotechnology Laboratory of the Marine Sciences Centre at the University of Basra for facilitating the research work and Prof. Dr. Bannai, M.A., for the identification of parasites.

#### Biography

##### Nadia Ali Al-Shammari

Biological Development Department, Marine Sciences Centre, University of Basra, Basra, Iraq, 009647722740914, nadia.ali.alshmeri@gmail.com

Miss Al-Shammari is an Assistant Lecturer at the Marine Sciences Centre Basra University, Basra, Iraq. She has written several research papers that have been published in English locally and internationally. She has published seven papers on Scope containers, specialising in fish diseases (bacterial). She has participated in several conferences, workshops and training seminars and is an ambassador and member of the research and academic platform IFAD. ORCID: 0000-0001-7295-9155.

#### References

- Al-Maleky, G.M. and Hanafi, R.A. (2013). Survey of aeromonas hydrophila in three marine fish species from North West Arabian Gulf, Iraq. *Journal of THI-QAR Science*, 3(4), 3–8.
- Al-Shemmari, N.A. (2017). *Isolation and Diagnosis of Bacteria Associated With Some Disease Infections in Some Fishes in Basra Governorate, Iraq*. Master's Dissertation, College of Agriculture, University of Basra, Iraq.
- Austin, B. and Austin, D.A. (2007). *Bacterial Fish Pathogens: Disease of Farmed and Wild Fish*. Chester: Springer. DOI: 10.1007/978-1-4020-6069-4.
- Bhagirathan, U. Panda, S.K. Meenakumari, B. Madhu, V.R. and Vaghela, D.T. (2012). Effects of bottom trawling on the ecological integrity of macrobenthos of Veraval, Gujarat. *Journal Marine Biological Association of India*, 54(1), 5–12. DOI: 10.6024/jmbai.2012.54.1.01528-0
- Carpenter, K.E. Krupp, F. Jones, D.A. and Zajonz, U. (1997). *FAO Species Identification Guide for Fishery Purposes. The Living Marine Resources of Kuwait, Eastern Saudi Arabia, Bahrain, Qatar, and the United Arab Emirates*. Rome: FAO Publications. Available at: <http://www.fao.org/docrep/010/v8729e/v8729e00.htm> (accessed on 11/11/2019).
- Cheesbrough, M. (2000). *District Laboratory Practice in Tropical Countries*. Parts 2. Cambridge: Cambridge University Press.
- CLSI, Clinical Laboratory Standards Institute (2006). *Performance Standards for Antimicrobial Disk Susceptibility Tests; Approved Standard (9<sup>th</sup> Ed)*. Wayne, PA: Clinical Laboratory Standards Institute.
- Darby, C. Jennifer, W.H., Nafisa, G. and Stanley, F. (2002). Caenorhabditis elegans: Plague bacteria biofilm blocks food intake. *Journal Nature*, 16(4), 243–4. DOI: 10.1038/417243a.
- Derome, N. Gauthier, J. Boutin, B. and Llewellyn, M. (2016). Bacterial opportunistic pathogens of fish. In: Hurst, C.J. (Ed.) *The Rasputin Effect: When Commensals and Symbionts Become Parasitic*. Switzerland: Springer. DOI: 10.1007/978-3-319-28170-4\_4
- Dias, M.K.R., Sampaio, L.S., Proietti, A.A., Junior, E.T.O., Yoshioka, D. P., Rodrigues, A.F.R., Rodriguez, R.A., Ribeiro, F.S., Faria, R.O.A., Ozório, M. and Tavares, D. (2016). Lethal dose and clinical signs of aeromonas hydrophila in arapaima gigas (Arapaimidae). *Journal Veterinary Microbiology*, 188(4), 12–5. DOI: 10.1016/j.sjbs.2017.10.019.
- Donia, G.R., Hafez, A. and Wassif, M. (2018). Studies on some heavy metals and bacterial pollutants in tilapia fish of El Salam Canal, Northern Sinai, Egypt. *Egyptian Journal of Aquatic Biology & Fisheries Zoology*, 21(4), 67–84. DOI: 10.13140/RG.2.2.18437.81121.
- Fehrenbacher, K., Huckaba, T., Yang, H.C., Boldogh, I. and Pon, L. (2003). Actin comet tails, endosomes and endosymbionts. *Journal of Experimental Biology*, 12(2), 977–1984. DOI: 10.1242/jeb.00240
- Guo, H., Stefanie, P., Glaeser, I.A., Jafargholi, I., Hossein, H.P. and Karl-Heinz, K. (2017). The abundance of endofungal bacterium *rhizobium radiobacter* (syn. agrobacterium tumefaciens) increases in its fungal host piriformospora indica during the tripartite symbiosis with higher plants. *Frontiers in Microbiology*, 8(629), n/a. DOI: 10.3389/fmicb.2017.00629.
- Hazen, T.C., Flierman, C.B., Hirsch, R.P. and Esch, G.W. (1978). Prevalence and distribution of *Aeromonas hydrophila* in the United States. *Appl. Journal of Environ. Microbiol.*, 36(5), 731–8.
- Hung, Y.T., Lee, T.A. and Huang, L.J. (2009). Clinical characteristics of patients with *Acinetobacter junii* infection. *Journal of Microbiology Immunology and Infection*, 42(1), 47–53. DOI:10.1007/s10096-012-1622-x.
- Jaafar, R.S. (2019). Bioremediation of lead and cadmium and the strive role of *Pediococcus pentosaceus* probiotic. *Iraqi Journal of Veterinary Sciences*, 34(1), 51–7.
- Janda, J. and Abbot, S. (2010). The genus *Aeromonas*: Taxonomy, pathogenicity, and infection. *Journal of Clinical Microbiology*, 23(1), 35–73. DOI: 10.1128/CMR.00039-09.
- Knochel, S. (1989). Effect of temperature on hemolysin production in *Aeromonas* spp. isolated from warm and cold environments. *International Journal of Food Microbiology*, 9(3), 225–35. DOI: 10.1016/0168-1605(89)90092-5.
- Lom, J. and Dykova, I. (2005). Microsporidian xenomas in fish seen in wider perspective. *Journal of Folia Parasitologica*, 52(1–2), 69–81. DOI: 10.14411/fp.2005.010.
- Manuel, J.B., Omar, A.C., Gabriela, I., Cecilia, H., Leda, I.P., Luis, U.G. and

- Graciela, C. (2019). Horizontal gene transfer and its association with antibiotic resistance in the Genus *Aeromonas* spp. *Journal of Microorganisms*, 7(9), 363. DOI: 10.3390/microorganisms7090363 .
- Marta, R., Damaso, C., Silva, J.E. and Almeida, M. (2011) Peritonitis due to *Rhizobium radiobacter*. *Journal of Einstein* (Sao Paulo), 9(3), 389–90. DOI:10.1590/S1679-45082011RC2025.
- Noga, E. J. (2010). *Fish Disease, Diagnosis and Treatment*. USA: Wiley-Blackwell. ISBN: 978-0-813-80697-6 .
- Oliver, K.M., Russell, J.A., Moran, N.A. and Hunter, M.S. (2003). Facultative bacterial symbionts in aphids confer resistance to parasitic wasps. *Journal Proc Natl Acad Sci USA*, 18(4), 1803–7. DOI:10.1073/pnas.0335320100.
- Olumide, A.O. and Ahmad, A. (2015). Antibiotic resistance profiling and phenotyping of aeromonas species isolated from aquatic sources. *Saudi Journal Biol Sci.*, 24(1), 65–70. DOI: 10.1016/j.sjbs.2015.09.016 .
- Putra, A.R., Effendi, M.H, Koesdarto, S., Suwarno, S. W., Tyasningsih, W. and Estroepangestie, A.T. (2019). Detection of the extended spectrum  $\beta$ -lactamase produced by *Escherichia coli* from dairy by using the Vitek-2 method in Tulungagung Regency, Indonesia. *Iraqi Journal of Veterinary Sciences*, 34(1), 203–7. DOI: 10.33899/ijvs.2019.125707.1134 .
- Romero, J., Feijóo, C.G. and Navarrete, P. (2012). *Antibiotics in Aquaculture – Use, Abuse and Alternatives, Health and Environment in Aquaculture*. Available at: <https://www.semanticscholar.org/paper/Antibiotics-in-Aquaculture> (accessed on 11/11/2019).
- Sreedharan, K.R. and Philip, I.S.B. (2012). Virulence potential and antibiotic susceptibility pattern of motile *aeromonads* associated with freshwater ornamental fish culture systems: A possible threat to public health. *Brazilian Journal of Microbiol*, 43(2), 754–65. DOI: 10.1590/S1517-83822012000200040
- Stratav, A. and Olumide, O. (2015). Antimicrobial resistance of *Aeromonas hydrophila* isolated from different food sources: A mini-review. *Journal of Infection and Public Health*, 9(5), 535–44. DOI: 10.1016/j.jiph.2015.10.006