

## Studies on eye affections among camels in Egypt: Clinical and bacteriological studies

Lotfia. S. Fahmy, A.A. Hegazy<sup>1</sup>, M.A.Abdelhamid ,M.E.Hatem<sup>2</sup> and A.A. Shamaa

Department of Surgery, Anaesthesiology and Radiology Department, Faculty of Vet. Med.  
Cairo University, Giza, Egypt.

<sup>1</sup>Department of Pathology , Faculty of Vet. Med., Cairo University, Giza ,Egypt.

<sup>2</sup> Department of Microbiology, Faculty of Vet. Med. ,Cairo University, Giza, Egypt

### Abstract:

Clinical and bacteriological studies were carried out on 260 out of 2500 camels from Sinai and El Fayoum provinces and police and military services "Hagana "in the period between 1986- 1996 . These animals presented with ocular affections of varying manifestations. Trials for treatment according antibiogram sensitivity test were performed .At the same time 100 healthy eyes were subjected to bacteriological examination to determine the normal ocular microflora. The ocular affections were differentiated according to the affected anatomical structures and bacteriological finding. The incidence of ocular disease was found to be 10.40. *Corynebacterium ulcerans*,*Streptococcus pyogenes* , *Moraxella Lacunata*, *Proteus mirabilis* and *Pseudomonas aeruginosa* were only isolated from diseased cases.

### Introduction:

Eye affections such as conjunctivitis, keratitis, endophthalmitis, uveitis and panophthalmitis are commonly reported among animals. (Gellat1981; Slatter, 1981 and Severin, 1984).

Recently many investigators have studied the camel in health and disease (Ramadan, 1994) but little attention has been paid to eye diseases in this species. The objective of the present study was to investigate the different types of camel eye affections, describe the clinical symptoms, identify the etiological agents and propose suitable treatment.

### Material and methods:

The present investigation was carried out on 2500 camels from Sinai and El Fayoum provinces, and from herds of the police and military services "Hagana" in the period between March 1986 till April 1996. 260 camels suffered from different ocular afflictions. These affected camels were subjected to clinical and bacteriological investigations. Treatment trials

were performed on the diseased cases. From the apparently normal camels, 100 camels with healthy eyes were subjected to bacteriological examination to determine the normal microflora of the camel's eye.

### **I- Clinical Examination:**

Ocular examination was carried out after physical restraint of the camels. The examination was facilitated in some cases by the use of a tranquilizer (Xylazine) at dose of 0.025 mg/kg intramuscularly and topical application of surface anesthesia (Benoxinate HCl 0.3%). The eyes were examined at day light for presence of ocular discharge, congestion, conjunctival swellings and eyelid lesions. After application of the fluorescein drops, the eye was irrigated using saline solution. Corneal ulcers amid wounds revealed green coloration. The interior of the eye specially the anterior chamber, iris and lens were examined using direct ophthalmoscope. However, the vitreous, retina and optic nerve could not be examined in open desert (*Slatter, 1981* and *Severin, 1984*).

Patency of the nasolacrimal drainage system and tear drainage was clinically evaluated in the camels using fluorescein passage test. Five drops of 4% fluorescein dye were instilled into the eye of the camel. A cotton swab was packed up the nostril and examined every five minutes for half an hour to detect the presence of the dye. A negative reading was indicated by non-passage of the fluorescein dye while a positive one was indicated by passage of the dye (*Magrane. 1974* and *Slatter, 1981*).

### **II- Microbiological study:**

The eyes of the 260 camels suffering from ocular affections and 100 control camels with healthy eyes were subjected to microbiological investigations.

*Sampling:* -

After restraining the animal the eyelids were carefully wiped with dry cellulose paper and set apart, then a sample was taken from the lower conjunctival sac using sterile cotton swabs. Swabs were also taken from corneal lesions while impression smears were taken and stained using Gram-stain (*Konemau et al, 1979*).

### **Bacteriological Examination:**

Swabs obtained from the eyes were directly inoculated onto nutrient broth

and incubated at 37 °c for 18-24 hours, then streaked onto the following media:

- 1- 10% sheep blood agar for isolating and differentiating haemolytic organisms.
- 2- Mac-Conkey's agar plates for demonstrating lactose versus non-lactose fermenting micro-organisms.
- 3- Chocolate agar plates for isolation of *Moraxella* spp and *Bordetella* spp.
- 4- Mannitol salt agar medium for selective isolation of pathogenic staphylococci and to test aerobic mannitol fermentation.
- 5- Hekton enteric agar medium as a selective and differential medium for Enterobacteriaceae and *Pseudomonas* spp.
- 6- 0.5% soft agar: nutrient broth plus 0.5% agar agar for preservation of the isolates along the course of the work.
- 7- Mueller Hekton agar medium for determination of bacterial sensitivity test.

#### **Identification:**

The inoculated plates were examined and selected colonies were picked up for further identification. The bacterial isolates were classified morphologically according to the colonial appearance and Gram staining reaction. The isolated bacteria were biochemically identified according to the following procedures:

- a- *Corynebacterium* according to Koneman et al (1979)
- b- Staphylococci according to Buchanan et al (1974).
- c- Streptococci according to Buchanan et al (1974).
- d- Members of family Enterobacteriaceae according to Scott et al (1978).
- e- Gram-negative rods including *Pseudomonas* spp. and *Moraxella* spp. According to Cruikshank et al (1975)
- f- Gram-negative cocci including *Neisseria* spp. According to Scott et al (1978).

#### **Antibiotic sensitivity test:**

In-vitro determination of the sensitivity of different bacterial isolates to different antibiotics was carried out according to Finegold and Martin (1982). The following standardized discs (blomex) were used:

Bactracin, Chloramphenicol, Carbenicillin, Erythromycin, Gentamicin,

Kanamycin, Nanamycin, Polymixin B, Streptomycin, Tetracycline and Trimethoprim-sulfamethoxazole (Septrim).

### **III- Treatment:**

The line of treatment for all ocular diseases in the present study was based on bacterial sensitivity tests that were performed on the isolates.

The following medicaments were used:

1. Cleansing solution (Boric acid 4%) for flushing the conjunctival sac and removing ocular discharge.
2. Astringent agent as Zinc sulphate 0.5% was used mainly in follicular conjunctivitis.
3. Mydriatic as Atropin sulphate eye ointment (1% Atropin sulphate).
4. Topical anesthetic; Benoxinate HCl 0.4% (Thilo).
5. Antibiotics:
  - A- Terramycin eye ointment (Oxytetracycline 5 mg and polymyxin B) Pfizer,
  - B- Polyspectran (7.500 IU polymyxin B sulphate, 300 IU bacitracin and 5mg neomycin sulphate) Thilo.
6. Antibiotic-steroid ointment. viz Cambison eye ointment, Hoechst.
7. Other eye ointments for corneal affections such as Solcoseryl eye gel, Solco.
8. Corticosteroid therapy was performed in two steps: Topical steroid application using cortisone eye ointment 1% (Ciba) then subconjunctival injection of the steroid Dexamethasone (Cid).

Acute cases were treated using polyspectran until the results of bacterial sensitivity test were obtained. Thereafter, appropriate antibiotic to which the causative organism was sensitive was used. In chronic cases; the treatment was instituted after performing sensitivity test.

## **RESULTS**

### **Clinical Findings:**

Various ocular affections involving one or more layers of the eye including the adnexa were encountered in 260 out of the 2500 examined camels (10.4%). The percentages of these affections are presented in Table (1).

**Table (1)**  
**Number and incidence of ocular affections among 260 camels**

<b>I. Affections of eye lids</b>	<b>Number of cases</b>	<b>Incidence</b>
Blepharitis	36	13.7
<b>II. Affections of the conjunctiva</b>		
1. Acute conjunctivitis	98	37.6
2. Chronic exudative conjunctivitis	36	13.7
3. Follicular conjunctivitis	9	3.4
<b>III. Affections of the cornea</b>		
1. Keratitis		
a. Superficial keratitis	9	3.4
b. Pigmentary keratitis	13	5
c. Deep	5	1.9
d. Ulcerative keratitis	13	5
e. Keratoconjunctivitis	18	6.8
2. Corned wounds		
a. Nonperforating	13	5
b. Perforating	5	1.9
<b>IV. Panophthalmitis</b>	5	1.9
<b>TOTAL</b>	<b>260</b>	

#### **I. Affections of the eye Lids:**

36 camels presented with blepharitis which was found to be secondary to external parasitic infestation. These cases showed thickened eyelids, blepharospasm and epiphora together with chemosis of the conjunctiva. In four cases, tick infestation (*Hyalomma* species) spreading over the periphery of the lower eyelid was found (Fig I A). Other camels suffered from alopecia and hemorrhagic crusts along the upper eyelid, with signs of pruritis.

Microscopical examination of skin scrapings of the crusted eyelids revealed sarcoptic mites (fig. 1B). These cases were treated with eye washing with 4 % boric acid lotion and local application of teramycin eye ointment, in addition to the subcutaneous injection of antiparasitic drug (Ivermectin).

## **II. Affections of the conjunctiva:**

143 camels showed either acute or chronic conjunctivitis. The acute form was found in 98 cases while 36 cases suffered from chronic exudative conjunctivitis and 9 cases showed follicular conjunctivitis. The acute form was characterized by chemosis and congested bulbar conjunctival blood vessels which were tortuous and movable on palpation. The discharge was serous or seromucoid, and sometimes the eyelids were stuck together. Swelling and thickening of the eyelids were observed with marked pseudoptosis ( fig. 2a).

Treatment of acute conjunctivitis included the irrigation with boric acid 4% solution and topical application of antibiotic ophthalmic ointment (Gentamycin oculi 0.3% polyspectran) twice daily for 5 successive days. The chronic exudative form was characterized by the presence of follicles on the inner aspect of the eyelid. The follicles were pin -head in size, glistening and raised from the subconjunctival surface (fig.2 B).

The chronic exudative form was characterized by longstanding thickening of the eyelid, chemosis and protrusion of the conjunctiva (fig. 2 c&d). These cases were successfully medically treated by curetting the follicles with a fine curette under topical surface anesthesia (Benoxinate HCL 1 %). Zinc sulphate 0.5% eye drop was used as an astringent. An antibiotic ophthalmic ointment (Gentamycin 0.3%) was applied twice daily for 7 days.

## **III. Affection of the cornea:**

76 out of the 260 affected camels exhibited different corneal affections. 58 camels were affected with keratitis and 18 with corneal wounds.

### **1. Keratitis:**

The presenting cases were either ulcerative or non-ulcerative in nature. The non-ulcerative cases included 9 of superficial keratitis, 5 of deep keratitis 13 of pigmentary keratitis and 18 of keratoconjunctivitis.

#### **a. Superficial keratitis (9 cases)**

In 4 camels, this condition was characterized by corneal oedema and vascularization where the vessels came out from the limbus and ran towards

the center of the cornea; lacrimation, photophobia and blepharospasm were also observed. Fluorescein was negative. These cases were treated with cambison ointment twice daily for 7 days.

The other 5 cases suffered from superficial keratitis without vascularization. There were two cases of white maculae with corneal pigmentation which accumulated over the entire cornea with accompanying mucopurulent discharge (fig 3A). The cornea was negative for fluorescein test.

Antibiotic ophthalmic ointment with polyspectran was used twice daily for 7 days to control the infection, followed by corticosteroid therapy while the corneal opacity remained unchanged.

**b. Interstitial (deep) keratitis (5 cases)**

These cases were characterized by deep corneal opacity and vascularization. Vessels projected from the limbus and were seen directed towards the area of opacity. Miotic pupil and dull, darkened iris were observed. Photophobia, blepharospasm and profuse lacrimation were marked. Fluorescein test was negative. These cases were treated with cambison eye ointment as well as atropin sulphate 1% eye ointment twice daily for 10 days.

**c. Pigmentary keratitis (13 cases)**

This condition was characterized by brown pigmentation with corneal vascularization. The blood vessels extended from the limbus toward the center of the cornea in the form of islets (fig 3 C)

**d. Keratoconjunctivitis (18 cases)**

The clinical signs comprised hyperemia of the palpebral and bulbar conjunctival blood vessels and corneal oedema was accompanied by excessive lacrimation, epiphora and blepharospasm. Corneal oedema appeared to start from the limbus toward the center (fig.3 B). These cases were negative to the fluorescein test. They were treated by steroid antibiotic ophthalmic ointment (Cambison) twice daily after irrigation of the eye with boric acid 4%.

**e. Ulcerative keratitis(13 cases)**

In each of these cases, a central corneal ulcer with marked peripheral oedema was observed. The eye was tender and there was intense blepharospasm, accompanied by a mucopurulent ocular discharge (fig.4A&5B).The fluorescein test was positive for all examined cases.

Good results were obtained by using a special regimen where the eye was thoroughly cleaned with 4% boric acid lotion, then antibiotic ophthalmic ointment (polyspectran) in combination with solcoseryl eye jell was applied twice daily.

The ciliary spasm was controlled with 1% atropine sulphate ointment twice daily. After 5 days, fluorescein test was repeated and a negative result was obtained.

Topical corticosteroid therapy was started to minimize conical scarring. Healing was complete within two weeks.

**2. Corneal wounds:**

These conditions were either perforating or nonperforating:

**a. Nonperforating corneal wound (13 cases)**

Recent conical wounds were observed in 8 camels. The wound was found in the lower part of the cornea near the limbus in the region of the nasal canthus. Corneal oedema and excessive lacrimation were evident. In addition to these signs, blood in the anterior chamber was detected in 5 camels (fig. 5 A & B).The latter cases were positive to fluorescein. The remaining cases showed old corneal wounds with exuberant granulation tissue. The superficial vessels supplying the granulation tissue originated from the limbus (fig. 5 C).The rest of the cornea was apparently normal.

The first form was treated in the same way as corneal ulcer. The follow up of the second form was discontinued as the animals were sent to the slaughter house.

**b. Perforated corneal wound (5 cases)**

Perforated corneal wound with iris prolapse was observed in five animals. There was severe injection of the ciliary vessels giving a red halo around corneal opacity. The prolapsed iris appeared as a small fleshy protruding



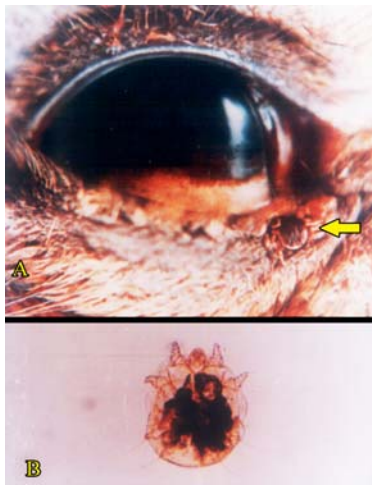


Fig. 1 **A.** Parasitic blepharitis due to the infestation of the lower eyelid with tick (arrow)  
**B.** Sarcoptic mite.

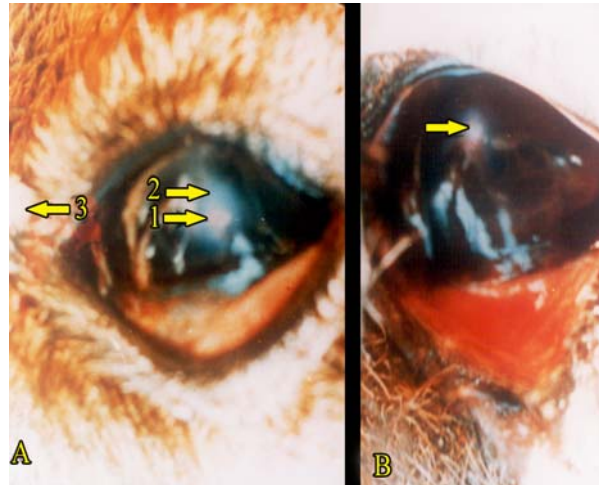


Fig. 2. **A.** Chronic conjunctivitis with the presence of seromucoid discharge at nasal canthus.  
**B.** Follicular conjunctivitis with many raised follicles on the palpebral conjunctiva of the lower eyelids (arrow)  
**C & D.** Chronic conjunctivitis with hypertrophied palpebral conjunctiva.

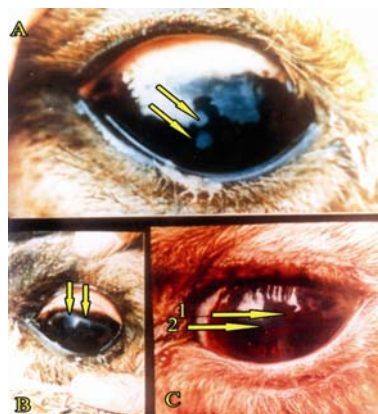


Fig. 3 **A.** Chronic superficial keratitis with two dots (arrows) and pigmentation of the cornea.  
**B.** Keratoconjunctivitis with marginal oedema of the cornea (arrow)  
**C.** Pigmentary keratitis 1. Excessive pigmentation of the cornea.  
 2. Corneal oedema.

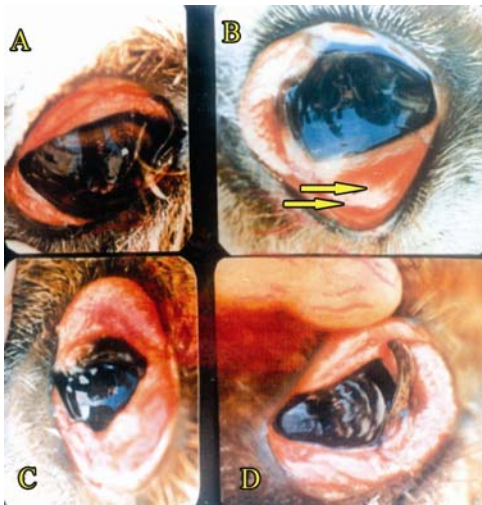


Fig. 4 A&B Ulcerative keratitis accompanied with  
 1. Superficial corneal ulcer.  
 2. Zone of infiltration.  
 3. Mucopurulent exudation.

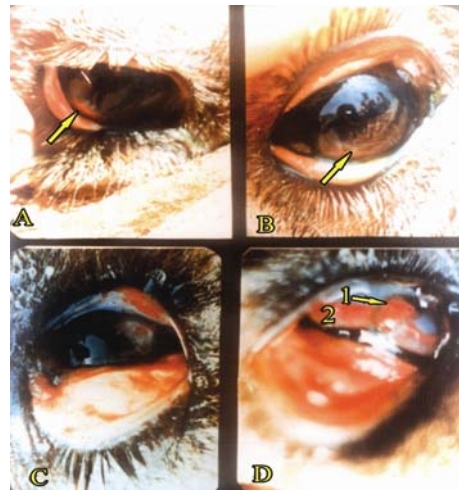

Fig. 5 **A.** Superficial corneal wound with hyphema.  
**B.** After treatment of case (A). Note the clearance of the anterior chamber and healing of the wound.  
**C.** Deep nonperforating corneal laceration with exuberent granulation and corneal vascularization (arrow)  
**D.** Perforated corneal wound accompanied with 1. Iris prolapse  
 2. Ciliar injection.

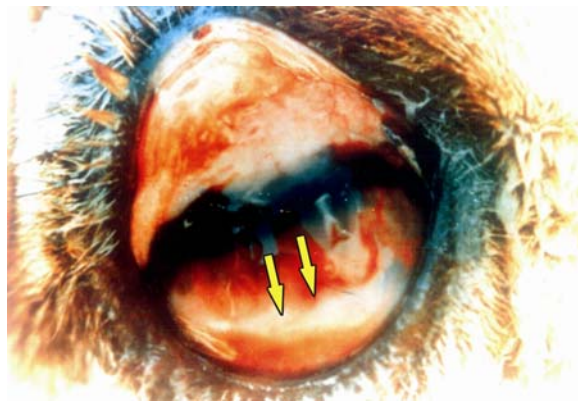


Fig. 6 Panophthalmitis. The turbidity of the anterior chamber and fibrine layer (arrow)

through the corneal wound. Hypopyon was also observed particularly in the lower part of the anterior chamber, and was accompanied by blepharospasm with mucopurulent ocular discharge (fig .5 D)

#### **IV. Panophthalmitis (5 cases)**

These cases were traumatic in origin. Initial ophthalmic examination - revealed excessive ocular discharge. The eye was fixed centrally. There was deep interstitial keratitis and the cornea was heavily vascularized. The conjunctiva was chemotic (fig. 6). Because of the extensive corneal oedema and vascularization, the anterior chamber, lens and fundus could not be detected. There was also ciliary injection.

#### **Bacteriological findings.**

A total of 306 bacterial isolates were recovered from the examined camels. The bacterial isolates in different cases are presented in table 2 and the incidence of bacterial isolates in normal and diseased camels is presented in table 3. The identity and incidence of the isolated bacteria were as follows: *Bacillus* spp (21.24%), *Staph. Aureus* (19.28%), *E. coli* (7.84%), *Branhamella (Nisseria) catarrhalis* (7.84%), *Strept. faecalis* (5.5 5%), *Klebsiella pneumoniae* (6.20%) *Staph. Epidemidis* (5.22%), *Proteus mirabilis* (4.24 %), *Coryne. ulcerans* (4.57%), *Coryne. Pseudotuberculosis* (3.59%), *A. pyogenes* (3.59 %), *Moraxella lacunata* (3.26%), *Proteus vulgaris* (3.59%), *Strept. pyogenes* (2.61 %), *Pseudomonas aeruginosa* (1.63%) and *Staph saprophyticus* (0.98%). A single isolate was obtained in 40 diseased cases, while mixed isolates occurred in 56 diseased camels. Normal camel eyes showed the following bacteria: *Bacillus Spp* (84 %), *E coli* (72%), *Staph aureus* (52%), *Staph. epidermidis* (32%), *Strept. faecalis* (16%), *Staph. saprophyticus* (16%), *Coryne. xerosis*, (12%), *Proteus vulgaris* (8%), *Coryne. pseudotuberculosis* (8%) and *Coryne. renale* (4%). It was found that *Coryne. ulceran*, *A. pyogenes*, *Strept. pyogenes*, *Branhamella (Nisseria) catarrhalis*, *Moraxella lacunata*, *Klebsiella pneumoniae*, *Proteus mirabilis* and *Pseudomonas aeruginosa* were isolated from the diseased camel eyes only.

**Table ( 2 )**  
**Isolated bacteria from diseased eyes of camels**

<b>Affection</b>	<b>No. of cases</b>	<b>Isolated bacteria</b>	<b>Number of isolates</b>	<b>%</b>
Blepharitis	36	<i>Staph. Aureus</i>	12	28.58
		Bacillus spp.	9	21.43
		<i>Corynepseudotuberculosis</i>	6	14.28
		<i>E. coil</i>	6	14.28
		<i>Klebsiella pneumoniae</i>	3	7.14
		<i>Strept. Faecalis</i>	3	7.14
		<i>Staph. Epidermidis</i>	3	7.14
		Total	42	7.14
Acute conjunctivitis	98	Bacillus spp.	24	24
		<i>Staph. Aureus</i>	20	20
		<i>Strept. Faecalis</i>	11	11
		<i>E.coli</i>	9	9
		<i>Branhamella catarrhalis</i>	7	7
		<i>A.pyogenes</i>	6	6
		<i>Proteus mirabilis</i>	4	4
		<i>Proteus vulgaris</i>	4	4
		<i>Klebsiella peneumoniae</i>	4	4
		<i>Staph. Epidermidis</i>	4	4
		<i>Coryne ulcerans</i>	3	3
		<i>Coryne pseudotuberculosis</i>	2	2
		<i>Pseudomonas aeruginosa</i>	2	2
		Total	100	2
Chronic conjunctivitis	39	<i>Branhamella catarrhalis</i>	9	23.08
		<i>Klebsiella pneumoniae</i>	9	23.08
		<i>Moraxella lacunata</i>	6	15.39
		<i>E. coil</i>	3	7.69
		<i>Staph. Epidermidis</i>	3	7.69
		<i>Staph. Saprophytica</i>	3	7.69
		<i>Strept. Faecalis</i>	3	7.69
		<i>Coryne pseudotuberculosis</i>	3	7.69
		Total	39	7.69
Chronic follicular conjunctivitis	9	<i>Klebsiella pneumoniae</i>	3	25
		<i>Staph. Aureus</i>	3	25
		<i>Staph. Epidermidis</i>	3	25
		Bacillus spp.	3	25
		Total	12	25
Superficial keratitis	9	<i>Staph. Aureus</i>	8	66.66
		Bacillus spp.	4	33.33

		<b>Total</b>	12	
Deep keratitis	5	<i>Staph. Aureus</i>	7	50
		Bacillus spp.	7	50
		<b>Total</b>	14	
Pigmentary keratitis	13	<i>Staph. Aureus</i>	6	33.32
		<i>E. coli</i>	3	16.67
		<i>Proteus mirabilis</i>	3	16.67
		<i>Proteus vulgaris</i>	3	16.67
		Bacillus spp.	3	16.67
		<b>Total</b>	18	
Ulcerative keratitis	13	<i>Strept. Pyogen</i>	3	20
		<i>Coryne ulcerans</i>	3	20
		<i>Proteus mirabilis</i>	3	20
		<i>Pseudomonas aeruginosa</i>	3	20
		Bacillus spp.	3	20
		<b>Total</b>	15	
Kerato-conjunctivitis	18	<i>Branhamella catarrhalis</i>	8	40
		<i>Coryne ulcerans</i>	4	20
		<i>Moraxella lacunata</i>	4	20
		Bacillus spp.	4	20
		<b>Total</b>	20	
Non perforating corneal wound	13	Bacillus spp.	3	16.67
		<i>Staph. Aureus</i>	3	16.67
		<i>Coryne ulcerans</i>	3	16.67
		<i>Proteus mirabilis</i>	3	16.67
		<i>Staph. epidermidis</i>	3	16.67
		<i>E. coli</i>	3	16.67
		<b>Total</b>	18	
Perforated corneal wound	5	<i>A. Pyogenes</i>	5	50
		Bacillus spp.	5	50
		<b>Total</b>	10	
Panophthalmitis	5	<i>Strept. Pyogenes</i>	5	100
		<b>Total</b>	5	
<b>Total</b>	<b>260</b>	<b>260</b>	<b>306</b>	

**Table ( 3 )**  
**Incidence of bacteria isolated from diseased and normal eyes of camels**

Isolated bacteria	Diseased eye (260 case)		Normal control eye (100)	
	Number of cases	%	Number of cases	%
Bacillus spp.	65	21.24	21	84
<i>Coryne xerosis</i>	-	-	3	12
<i>Coryne ulcerans</i>	14	4.57	-	-
<i>Coryne ovis</i>	11	3.59	2	8
<i>Coryne pyogenes</i>	11	3.59	-	-
<i>Coryne renals</i>	-	-	1	4
<i>Staphylococcus aureus</i>	59	19.28	13	52
<i>Staphylococcus epidermidis</i>	16	5.22	8	32
<i>Staphylococcus saprophyticus</i>	3	0.98	4	16
<i>Streptococcus faecalis</i>	17	5.55	4	16
<i>Streptococcus pyogenes</i>	8	2.61	-	16
<i>Branhamella catarrhalis</i> *	24	7.84	-	-
<i>Moraxella lacunata</i>	10	3.26	-	-
<i>E. coil</i>	24	7.84	18	72
<i>Klebsiella pneumoniae</i>	19	6.20	-	-
<i>Proteus mirabilis</i>	13	4.24	-	-
<i>Proteus vulgaris</i>	7	2.28	2	8
<i>Pseudomonas aeruginosa</i>	5	1.63	-	-
	306		70	

\* *Neisseria catarrhalis*

### Discussion

While surpassing all other species in their adaptability to the environment, camels remain the most neglected domestic species. Camels survive, produce and work in the harsh environment of the desert. One of the reasons of neglect of camels is that they exist in underdeveloped areas or in countries where there are inadequate facilities for scientific research.

In the present investigation, the incidence of ocular diseases among examined camels in different localities in Egypt was found to be 10.4%. The incidence of ocular affection in camels is not well ascertained because

of the paucity of records. *Ismail, 1987* recorded 7 cases of camels suffering from ocular affections among 721 cases of various domestic animals.

In general, the incidence of ocular affection of camels appeared to be less than that of other ruminants which could be as high as 58% in calves (*Hubbert and Herman, 1970*) and 28% in cattle and buffaloes (*Soliman, 1974*). This could be due to the fact that eyes have accessory structures to enable the animal to accommodate to the most atmospheric changes of the desert (*Tayeb, 1962*). These structures are only modification and extension of structures present in other domesticated animals. They include enlargement of the eyelids, specially the upper, which hangs over both the eyeball and the lower lid, shading completely the eye against direct sun-rays.

Unlike other domestic animals, the lower lid of the camel is the one that moves freely. Another feature worth mentioning is the presence of numerous long, strong tactile hairs on the upper lids forming a dense brush like structure at the medial canthus.

These structures together with the densely arranged eye lashes constitute an efficient protecting apparatus against sand storms. From the anatomical point of view, the orbital cavity in the camel is formed of a nearly complete bony 2 with double walls in which the eye and its accessory structures are protected by a steep wall of muscular mass and fat. These anatomical modifications act as an air-conditioned room which protects the eye against inclement and sudden atmospheric changes. Observation of the living camel shows that it goes comfortably under scorching sun rays, opening its eyes by depression of the lower eyelid only, while the eyeball is retracted deeply under the upper lid by the aid of specialized conjunctival fold.

It is particularly important to mention that unlike other domestic animals, the lacrimal ducts of the camels open together in a wide tunnel like recess formed by the conjunctival fold just above the lateral canthus. This design naturally prevents blocking of the duct by sand and the eye could be easily washed. The present study revealed that the normal ocular flora of the camel is similar to that recorded among other domestic animals. Both pathogenic and non pathogenic bacteria were isolated from diseased eyes of camels were incriminated in the production of ocular affections, provided that trauma as a predisposing factor. *Branhamella catarrhalis*, *Moraxella*

---

*lacunata*, *Klebsiella pneumoniae*, *Proteus mirabilis*, *Coryn. ulcerans*, *A. pyogenes*, *Pseudomonas aeruginosa* and *Strepto.pyogenes* were isolated only from the diseased cases.

This emphasizes their role as the primary cause of such affection. Cases of blepharitis recorded in this study were secondary to parasitic infestation by ticks and mites. The symptoms were similar to those described in other domestic animals (Smyth 1958, Magrane 1974, Slatter 1981). Recovery of blepharitis was obtained after treatment of the primary cause as suggested by Severin (1984) with subcutaneous injection of ivermectin "Ivomec".

Conjunctivitis was the most common affection among the clinical cases. Similar findings were reported by Abdalla et al., (1971) in camel, and Smyth (1958) and Severin (1984) in other domestic animals.

Organisms isolated from acute cases of conjunctivitis in the camel determine to a large extent the clinical picture of the condition. In the mucopurulent form of the disease typical pyogenic organisms as *Coryne.pseudotuberculosis*, *A.pyogenes*, *Staph.aureus*, *klebsiella pneumoniae*, *Proteus mirabilis* and *pseudomonas aeruginosa* were isolated, while in the catarrhal form *Branhamella (Nisseria) catarrhals*, and *E. coil* were found. These findings are in agreement with Fedukowicz, (1978).

Chronic exudative conjunctivitis was more prevalent than the follicular form. This might be attributed to the mild irritation caused by adverse environmental conditions surrounding the animal. Moreover, *Branhamella (Nisseria) catarrhals* and *Moraxella lacunata* were isolated from 5 cases of chronic exudative conjunctivitis. These organisms are recorded for the first time in camel, and could well be the cause of chronic exudative form, as reported by Scott et al., (1978) in other domestic animals.

Keratitis occupied the second place after conjunctivitis in relation to the total number of the reported ocular affections. All reported ocular affections showed symptoms similar to those of other domestic animals (Magrane, 1974, Slatter, 1981, Severin, 1984, Misk, et al., 1986, and Ismail, 1987)

The site of the corneal ulcer was usually in the lower quadrant of the cornea in the area of the nasal canthus; this might be attributed to the fact



that the upper eyelid is thick and covers the upper two thirds of the cornea (Tayeb,1962).

With regard to the treatment, all the aforementioned conditions respond to treatment except the pigmentary form. This was also reported by Slatter, (1981) and Ismail, (1984). Solcoseryl proved to be a good medicament for ulcer treatment. Similar observations were made by Rifat et al.,(1978). For minimizing the corneal scar, the use of cortico -steroid therapy is advised (Slatter, 1981 and Severin ,1984).

Panophthalmitis may be considered one of the complications of neglected corneal wounds. *Strept.pyogenes* was isolated from these cases .Fedukowics, (1978) reported that infection with streptococcus sp. usually occurred following trauma and leads to panophthalmitis.

The present investigation revealed that the fluoresceine substance failed to reach the nasal cavity after ocular administration. This negative result could be explained by the absence of the lacrimal puncta in the camel while both lacrimal canaliculi are non patent .Similar results were reported by Awkati,(1971),Abdalla et.al.,(1971) and Saber and Makady, (1987).

**References:**

1. Abdalla,O.,M.F.A. and Arnautovic, I (1971): "**An anatomical study of the lacrimal apparatus of the one humped camel**" . Acta. Anat. 75,648-650.
2. Buchanon, R.E. and Gibbons, N.E. (1974): "**Bergey's~manual of determinative bacteriology.**" 8th Ed. Williams & Wilkin' s Co. Baltimore.
3. Cruickshank, R., Dugid, J.R., Marmian, B.P. and Swain, R.H. (1975): "**Medical microbiology ( A guide to laboratory diagnosis & control of infection )** 7th Ed., English Language Book Society Edition. London.
4. Fedukowicz. H.B. (1978): **External infections of the eye.** 2nd Ed. Appleton- Century- Crofts, U.S.A.
5. Finegold, S.M. and Martin, W. J. (1982): "**Diagnostic Microbiology**" C.V. Mesby Company.
6. Gellat, K.N.,(1 981):**Veterinary ophthalmology** Lea and Febiger Philadelphia
7. Hubbert, W.T. and Hermann, G.J. (1970): **A winter epizootic of infectious bovine keratoconjunctivitis** J. Amer. Vet. Med. Ass. 127, 452-454.
8. Ismail,S.F.(1984): **Studies on some eye affections in domestic animals with special reference to their causative agents** M.D.Thesis Faculty of Veterinary Medicine Assuit University, Egypt
9. Ismail , S.F. (1987): "**Further studies on eye affections in some domestic animals with special reference of some surgical techniques** ." Ph. D. (Vet) Thesis Faculty of Veterinary Medicine Assiut University , Egypt.
10. Koneman, Allen , Dowell and Sonners (1979): "**Colour Atlas and Textbook of Diagnostic Microbiology.**" J.B. Lippincott company, Philadelphia, Toronto.
11. Magrane, W.G. (1974): "**Canine Ophthalmology**". 2nd Ed. Lea & Febiger, Philadelphia.
12. Misk, N.A. and Ismail S.F. (1986b): **Surgical management of some ocular disease in buffaloes , cattle and sheep.** Vet. Med. Rev. 1, 55
13. Ramadan,O.R(1994):"**Surgery and radiology of dromedary camel.**" Al-Jawad printing press Al-Ahasa Kingdom of Saudi Arabia

14. Rifat, I.F. abbas, B.T and soliman, A.S. (1987) **The use of solcoseiyl for the treatment of corneal ulcer and opacity in a camel** Egypt. Med. Assoc. J 35 132-141
15. Round, M.C. (1962): **The helminth parasites of domesticated animals in Kenya.** J. Helminth 36. 375.
16. Saber, A.S and Makady, F. M (1987) **Anatomical and clinical studies on lacrimal system in the camel** Assuit. Vet. Med. J. 37 18-24
17. Scott, E.G., Martin, W.J. and Finegold, S.M. (1978): **“ Diagnostic Microbiology”** The C.V. Mosby Company.
18. Severin, A.C. (1984) : **“ Veterinary Ophthalmology Notes.”** 2nd Ed. Colorado State University
19. Slatter, D. (1981): **“Fundamentals of veterinary Ophthalmology”**. B W. Saunders, Philadelphia.
20. Smyth, R.A. (1958): **“Veterinary Ophthalmology.”** 2nd Ed. London.
21. Soliman, A.S. (1974): **Studies on some prevalent eye affections of cattle and buffaloes** M.D. (Vet) Thesis. Faculty of Veterinary Medicine, Cairo University, Egypt.
22. Tayeb, M.A.F. (1962): **The eye of the camel as an animal adapted to live in the desert** Vet. Med. J. 2, 135-15 1

( )

لطفية فهمى ، على حجازى، محمد عياد و اشرف شمعة

قسم الجراحة والتخدير والأشعة و قسم الأمراض

كلية الطب البيطرى . جامعة القاهرة . الجيزة ج.م.ع

### الملخص :

اجريت دراسات اكلينيكية و جرثومية على عدد ٢٦٠ من بين ٢٥٠٠ حيوان  
بمنطق سيناء و الفيوم وقوات البوليس والجيش (الهجانة ) خلال الفترة ما بين  
١٩٨٦.١٩٩٦ . هذه الحيوانات بها اعراض لإصابات العين . اجريت محاولات علاجية  
اعتمادا على اختبار الخساسة . وبالتزامن اجرى تحصن جرثومى لعدد مائة من الأبل  
الضوابط للتعرف على البكتريا المتواجدة طبيعيا بالعين تبعا للتركيب التشريحي  
ونتائج الفحوص البكتريولوجية . نسبة الأصابات المرضية بالعين كانت ١٠.٤٠٪ . تم  
عزل البكتريا الوتدية التقرحية ، المكورة السبحية الصديدية والزوائف المنتجة للهواء  
*moraxella lacunata ,proteus mirabilis* من الحالات المريضة .